

ADENOCARCINOMA, PRIMARY IN THE LUNG VERSUS METASTATIC IMMUNOHISTOCHEMICAL MARKERS

ADINA CIURSAȘ*¹, T.T.MAGHIAR¹, M. PUȘCAȘIU^{1,2}, GABRIELA MUȚIU¹, P DEME³

University of Oradea, Medicine and Pharmacy Faculty, Department of Morphological Sciences¹,
 Pelican County Hospital of Oradea, Clinical Service of Pathology²
 Western University of Vasile Goldis, Arad, Medicine, Dental Medicine and Pharmacy Faculty, Department of
 General Medicine, Anatomy³

Correspondence address*:

Adina Ciurșas* M.D. – univ. asistent on Department of Morphological Sciences,
 Faculty of Medicine and Pharmacy, University Oradea, street December 1, Oradea,
 Romania

Adina Ciurșas: street Călugăreni nr. 8, bl.C2, ap. 40, Oradea Romania mobile
 phone: 0728 003 426, e – mail: adina.ciursas@gmail.com,

Pelican County Hospital of Oradea, Clinical Service of Pathology, Corneliu
 Coposu street nr.2, phone:0259 422078 Oradea, Romania

ABSTRACT. The aim of this study was to use a pannel of antibody/ immunohistochemical markers four lung adenocarcinoma such as Ck 7, Ck 20, TTF – 1, and CD – 15, CEA in differentiating primary from metastatic lung adenocarcinoma. The immunohistochemical markers should always be used in conjunction with the clinical presentation, distribution of the lesions, and the morphology. Have been under study 292 patients with lung carcinoma and in 86 (29,45 %) cases we found adenocarcinoma. On these cases we use a pannel of immunohistochemical markers: Ck 7, Ck 20, TTF- 1, and CD – 15, CEA. Of the 86 lung adenocarcinoma specimens there were 40 primary lung adenocarcinomas, 16 metastatic adenocarcinomas from breast and 30 metastatic adenocarcinomas from colon. We have found that 70% of primary lung adenocarcinomas expressed TTF – 1, whereas all nonpulmonary adenocarcinomas lacked TTF – 1 staining. A combination of TTF – 1+/ Ck 7 +/ Ck 20 –/ was highly significantly associated with primary adenocarcinoma of lung. A combination of TTF – 1 –/ Ck 7 –/ Ck 20 +/ was highly significantly associated with adenocarcinoma of gastrointestinal origin. Our study has confirmed that expression of Ck 7 , Ck 20, TTF – 1 and CD – 15, CEA are useful immunohistochemical markers for diagnosis of lung tumors and for differential diagnosis of primary lung adenocarcinomas from metastatic lung adenocarcinomas .Application of this panel of antibodies might be expected to increase the accuracy of diagnosis.

RESUME. Le but de cette étude était d'utiliser un pannel d'anticorps/ immunohistochemical adénocarcinome de poumon marqueurs quatre comme Ck 7, Ck 20, TTF-1, et CD – 15, CEA pour différencier les primaires de l'adénocarcinome du poumon métastatique. Les marqueurs immunohistochimiques doivent toujours être utilisés de concert avec le tableau clinique, de la distribution des lésions et la morphologie. Nous avons étudié 292 cas de cancer du poumon et dans 86 cas était l'adénocarcinome du poumon diagnostiqués. Ces cas ont utilisé les marqueurs suivants à notre connaissance: Ck 7, Ck 20, TTF – 1, CD – 15, CEA. Les 86 cas d'adénocarcinome du poumon, 40 étaient adénocarcinome pulmonaire primaire, 16 adénocarcinome métastatique du sein, 30 adénocarcinome métastatique du côlon. Il a été constaté que 70 % des adénocarcinome pulmonaire primaire ont exprimé le TTF – 1, tout en extrapulmonaire n'expriment pas le TTF – 1. Une combinaison d'u TTF – 1 +/ Ck 7 +/ CK20 –/ était très significativement associée à adénocarcinome pulmonaire primaire. Une combinaison de TTF – 1 –/ CK7 –/ Ck 20 + est très significativement associée avec adénocarcinome d'origine digestive. Notre étude a montré que l'expression Ck 7, Ck 20, TTF – 1, et CD – 15, CEA sont à notre connaissance, des marqueurs utiles dans le diagnostic des tumeurs du poumon et adénocarcinomes pulmonaires de différenciation de l'adénocarcinome de métastatique pulmonaire primaire. Application de ce groupe d'anticorps peut augmenter la précision du diagnostic.

KEYWORDS: lung carcinoma, adenocarcinoma,; Ck 7, Ck 20, TTF – 1, CD – 15, CEA

INTRODUCTION

Adenocarcinoma has surpassed squamous carcinoma as the most common histologic subtype of lung cancer in many countries { Colby TV, Koss M, Travis WD, 1995}. Although most cases are seen in smokers, it develops more frequently than any other histologic type of lung cancer in individuals (particularly women) who have never smoked {Colby TV, Koss M, Travis WD (1995), Khuder SA (2001)}

Incidence rates, and the estimated rates by histological subtype have been reported for 30 populations for which a relatively high proportion of cases had a clear morphological diagnosis {Parkin DM, Whelan SL, Ferlay J, Teppo L, Thomas DB (2002)}. Among men, only in certain Asian populations (Chinese, Japanese) and in North America (USA, Canada) does the incidence of adenocarcinoma exceed that of squamous cell carcinoma. In women, however, adenocarcinoma is the dominant histological type almost everywhere, except for Poland and England where squamous cell carcinomas predominate, and Scotland where small cell carcinoma is the most frequent subtype {Parkin DM, Whelan SL, Ferlay J, Teppo L, Thomas DB (2002)}. Adenocarcinomas are particularly predominant in Asian females (72% cancers in Japan, 65% in Korea, 61% in Singapore Chinese). The differences in histological profiles are strongly influenced by the evolution of the epidemic of smoking-related lung cancer over ti

PATIENTS AND METHODS

Have been under study 292 patients with lung carcinoma of Clinical Emergency County Hospital Oradea in the period 2009-2013. All patients were drawn up an evaluation and a consent. Each patient had clinical and paraclinical examination conducted: pulmonary radiography, bronchoscopy exploratory and pulmonary diagnostics for the purpose of sampling for biological materials – distal bronchi subsegmentare biopsy of grade 5-6, including tracheo-bronchi pulmonary biopsy or lymph node biopsy, the usual staining and immunohistochemic specific markers for diagnosis of primary versus metastatic lung adenocarcinoma.

The selection criteria of the patients included in the immunohistochemical study of primary versus metastatic adenocarcinoma were:

- patients who had been diagnosed with adenocarcinoma in the emergency County Hospital Oradea, and on the basis of immunohistochemical markers that were performed in Clinical Pathology Service from Pelican County Hospital.
- patients have consented their introduction in the study after they have been explained ethical criteria, scientific, and confidentiality

Exclusion criteria:

- patients with lung carcinoma other than lung adenocarcinoma
- patients who have refused invasive medical procedure, respectively bronchoscopy and pulmonary biopsy
- uncooperative patients

Bronchoscopy

For diagnosis of lung carcinoma has been chosen as a method of investigation of the 292 cases (2009 – 2013) in the emergency County Hospital Oradea, bronchoscopy and biopsy. Bronchoscopy is considered to be a method of imaging diagnosis for lung cancer, in particular with central location. It allows you to view the direct lung traheal, main lobar bronchies and segmentation and obtain information on lesion headquarters, the infiltrative character, obstructive and/or bleeding, the extension to proximal (indispensable to stage, surveillance), existence of compression associated or at the level of carina. So they were taken over pulmonary biopsy.

Specimen and staining procedure

Human biological material represented by fragments of lung tissue taken by pulmonary biopsy via bronchoscopy have been subjected to classical histological techniques, namely the processing mounting in 10% buffered formalin at neutral pH, followed by paraffin embedded.

The paraffin blocks were sectioned at 5 micrometer and were stained with hematoxylin and eosin (*fig 1*) and by immunohistochemical markers in accordance with usual algorithm in Table 1. Slides were stained immediately because antigenicity of cut sections may diminish over time. To our knowledge, the immunohistochemical markers (Ck 7, Ck 20, TTF – 1, CD – 15 and CEA) were performed at the Clinical Pathology Service from Pelican County Hospital.

Section	Stain	Purpose
1	<i>Hematoxylin- Eosin</i>	<i>Morphological diagnosis</i>
3	<i>Ck 7 – rabbit monoclonal primary antibody</i>	
4	<i>Ck 20 – rabbit monoclonal primary antibody</i>	
5	<i>TTF – 1 – mouse monoclonal primary antibody</i>	
6	<i>CEA</i>	
7	<i>CD 15 – mouse monoclonal primary antibody</i>	

Table 1 – The stain algorithm

RESULTS

Anti – Ck 7 was raised against the carboxil terminal region of Ck 7 human protein spanning amino acids 451 – 469. Ck7 is a tipe II keratin that serves as a structural protein expressed by most of ductal, glandular and transitional epithelia. Ck 7 exhibits a cytoplasmic localization. This antibody may be used to aid in the identification of normal and neoplastic cells of ovary, lung (*fig.2*) and breast epithelial origin which express Ck 7, and those of colonic (*fig. – 5*) and prostate epithelial lineage which lack Ck 7 production.

Anti – Ck 20 is a monoclonal antibody against the carboxil region of the human Ck 20, type I cytokeratin protein of mature enterocytes and goblet

cells of the gastric and intestinal mucosa. This antibody produces a cytoplasmic staining pattern, and may be used to aid in the identification of normal Ck 20 expressing cells and neoplastic (*fig.6*) cells of colonic epithelial lineage.

Ck 7 used in conjunction with Ck 20, metastasis from the mucinous epithelium and urothelium of gastrointestinal and prostatic lineage as well as some transitional cell carcinomas, and Merkel cell tumors can be differentiated from primary neoplasm of tissue normally expressing CK 7 {Rubin BP, et al. (2001), Wang HL, et al. (2001), Inamura, K. Et al. (2005), Rekhi, B. et. al. (2008), Rossi, G. et al. (2007), Sack M. J, et al. (1997), Tsao SC, et al. (2007)} – *table 2*.

Section	Immunohistochemical Markers	Primary tumor indication
1	CK 7+/CK 20-	favors lung primary* - <i>figure 2 &3</i>
2	CK 7+/CK 20+	strongly favors transitional cells (urothelial) carcinoma*
3	CK 7-/CK 20+	favors colorectal carcinoma* - <i>figure 5&6</i>
4	CK 7-/CK 20-	no primary indication*

Table 2 – Common immunohistochemical markers associated with primary tumor indications

* { Rubin BP, et al. (2001), Wang HL, et al. (2001), Inamura, K. Et al. (2005), Rekhi, B. et. al. (2008), Rossi, G. et al. (2007), Sack M. J, et al. (1997), Tsao SC, et al. (2007) }

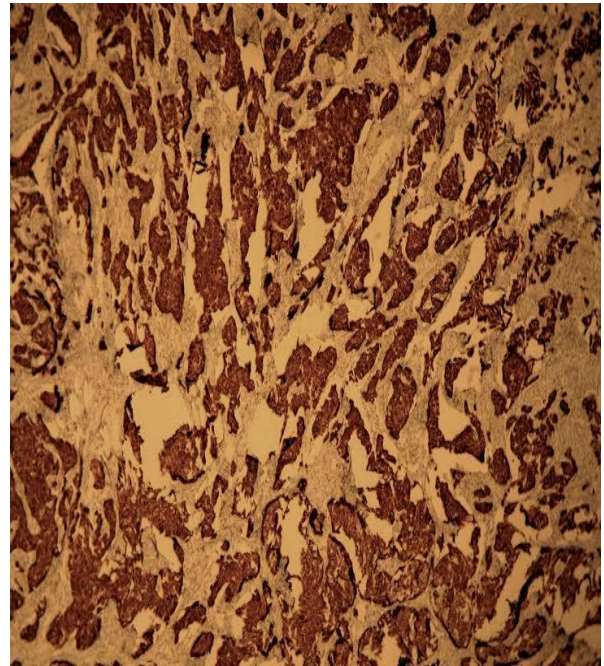
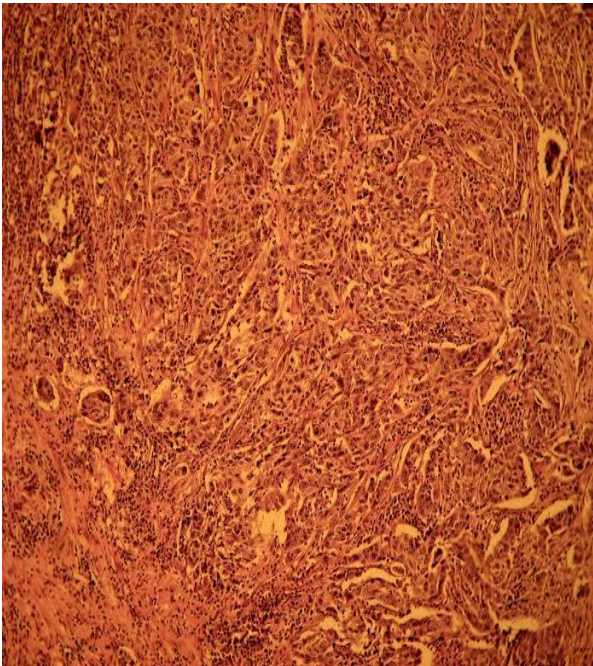
TTF – 1 is a 38 KD nuclear protein member of the family of homeodomain transcription factors. Exclusive expression in epithelial cells of the thyroid gland and lung allows TTF – 1 to be a usefull antibody for the classifications of tumors arising in these organs. Antibody to TTF – 1 demonstrates an intranuclear staining pattern. In context with other data TTF – 1 becomes useful in the investigation of metastatic adenocarcinomas of an unknown origin { Ordonez N (2001) } – (*fig. 7*).

TTF – 1, a transcription factor that plays an important role in the lung specific expression of surfactant proteins, is expressed in up to 75% of lung adenocarcinomas { Zamecnik J, Kodet R (2002) }.

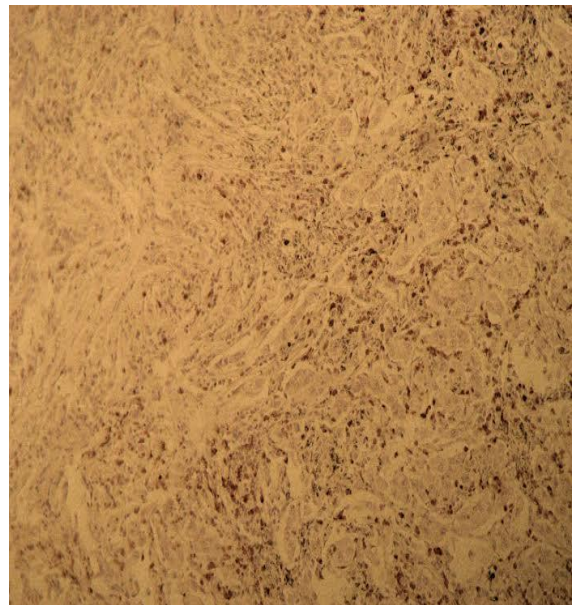
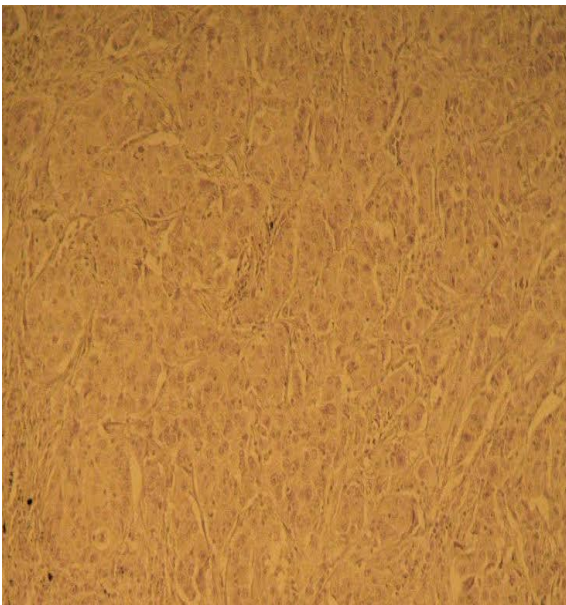
Anti CD 15 mouse monoclonal primary antibody is a mouse monoclonal antibody direct against a carbohydrate epitope present on most

granulocytic cells. Helps differentiate lung adenocarcinoma (CD15 +) - (*fig. 4*) from mesothelioma (CD15), although other markers are more specific.

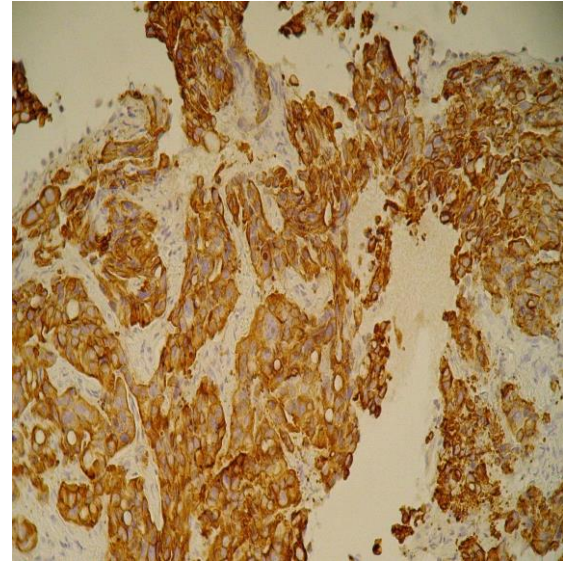
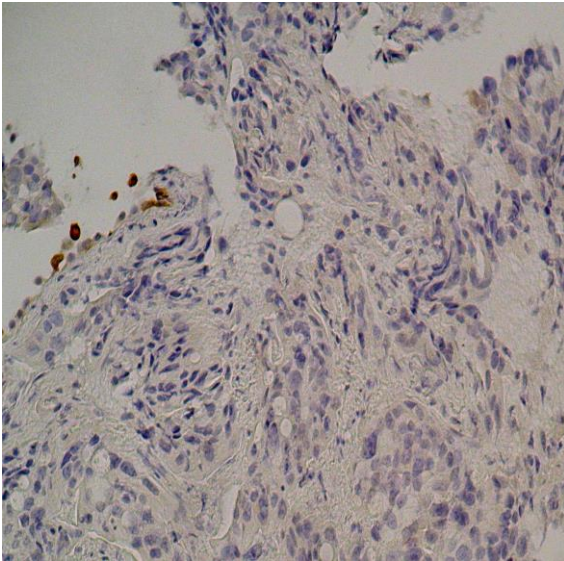
CEA, carcinoembryonic antigen normally detected in glycocalyx of fetal epithelial cells. May play a role in the metastasis of cancer cells. Usually considered an epithelial marker with strong staining in adenocarcinomas. Used by pathologists in lung adenocarcinoma versus epithelioid mesothelioma: monoclonal CEA is 97% specific for lung adenocarcinoma (Histopathology 2006;48:223); exhibits diffuse cytoplasmic staining with membrane enhancement in adenocarcinoma, negative in mesothelioma; in breast cancer versus benign breast disease in FNA fluid: high levels are suggestive of malignancy (Arch Pathol Lab Med 2004;128:1251); in colorectal carcinoma – (*fig 8*)



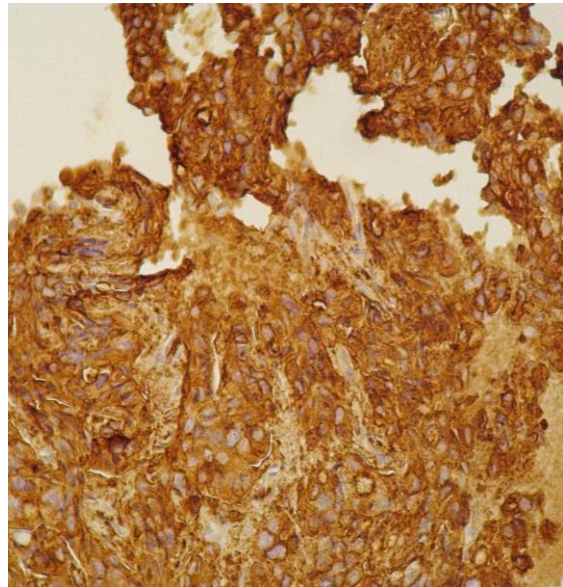
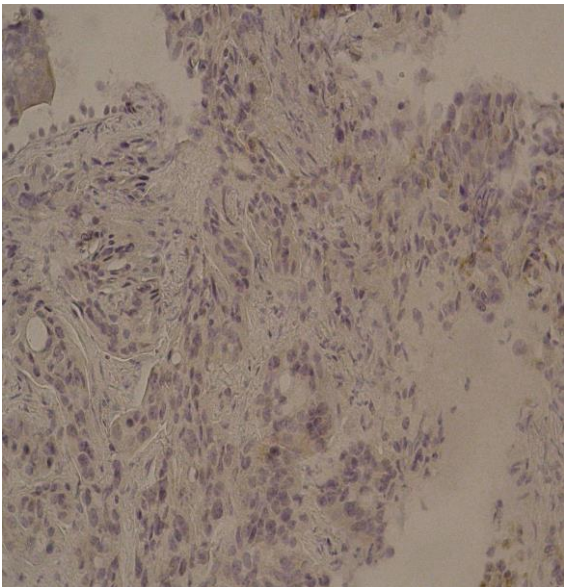
Primary lung adenocarcinoma: Fig. 1–H&E Ob.20x.& Fig.2. Ck 7 + Ob. 20x



Primary lung adenocarcinoma: Fig 3 Ck 20 – Ob. 20x Fig 4. CD – 15 + Ob. 20x



Metastatic lung adenocarcinoma: Fig. 5 Ck 7 – Ob. 20x. Fig. 6 Ck 20 + Ob. 20x.



Metastatic lung adenocarcinoma: Fig. 7 TTF – 1 – Ob. 20x. Fig. 8 CEA + Ob. 20x

DISCUSSION

The immunohistochemical features of adenocarcinomas vary somewhat with the subtype and the degree of differentiation.

Primary adenocarcinomas of the lung usually exhibit Ck 7 and Ck 20 cytoplasmic immunoreactivity.

70 % of primary lung adenocarcinomas exhibit nuclear TTF – 1 immunoreactivity.

By using a pattern of immunohistochemical markers such as, Ck 7, Ck 20, TTF – 1, and CD – 15, and CEA was possible to narrow the primary site of a metastatic adenocarcinoma in the lung. Application of this panel of antibodies might be expected to increase the accuracy of diagnosis.

On the basis of this study it was found that from 292 cases of lung carcinoma we found: squamous carcinoma in 139 cases (47,60 %), adenocarcinoma in 86 cases (29,45 %), adenosquamous carcinoma in 6

cases (2,05%), small cell carcinoma in 49 cases (16,78 %) and large cell carcinoma in 12 cases (4,12).

In our study the dominant histological type blanket from lung carcinoma in most common underlying cause is squamous carcinoma (47,60%) and not adenocarcinoma (29,45 %) as – reported in the literature .Probably this reversal of the reports shall be produced by eliminating smoking in developed countries, and is also aware of the fact that most common underlying cause is squamous carcinoma in direct connection with the consumption of cigarettes, while adenocarcinoma appearance it has nothing to do with the consumption of cigarettes.

Another reason why the incidence of adenocarcinoma of the lung is less in our study than squamous cell carcinoma could it be that the majority of patients were investigated by bronchoscopy and lung adenocarcinoma occurs more frequently as peripheral nodules < than 4 cm { Colby TV, Koss M, Travis WD

1995, Fraser RS, Müller NL, Colman N, Pare PD (1999)).

They infrequently present in a central location as a hilar or perihilar mass and only rarely show cavitation. Pleura and chest wall involvement is seen in approximately 15% of cases and this is more frequent than with other forms of lung cancer. Hilar adenopathy is less frequent with adenocarcinoma than with other forms of lung cancer {Travis WD, Brambilla E, Müller-Hermelink HK, et al: Pathology and Genetics: Tumours of the Lung, Pleura, Thymus and Heart. Lyon, France, IARC, 2004}.

FIGURE LEGEND

Table 1 – The stain algorithm

Table 2 – Common immunohistochemical markers associated with primary tumor indications

- Fig. 1** Primary lung adenocarcinoma – H&E Ob.20x.
Fig. 2 Primary lung adenocarcinoma – Ck 7 + Ob. 20x
Fig. 3 Primary lung adenocarcinoma Ck 20 – Ob. 20x.
Fig. 4 Primary lung adenocarcinoma CD – 15 + Ob. 20x
Fig. 5 Metastatic lung adenocarcinoma Ck 7 – Ob. 20x
Fig. 6 Metastatic lung adenocarcinoma Ck 20 + Ob. 20x
Fig. 7 Metastatic lung adenocarcinoma TTF – 1 – Ob. 20x
Fig. 8 Metastatic lung adenocarcinoma CEA + Ob. 20x

ABBREVIATIONS

- Citokeratin 7 (Ck 7)
 Citokeratin 20 (Ck 20)
 Thyroid transcription factor 1 (TTF – 1)
 Carcinoembryonic antigen (CEA)

REFERENCES

- Colby TV, Koss M, Travis WD (1995). Tumors of the Lower Respiratory Tract. 3rd ed. Armed Forces Institute of Pathology: Washington, DC,.
- Inamura, K. Et al. Pulmonary adenocarcinomas with enteric differentiation (2005). Histologic and immunohistochemical characteristics compared with metastatic colorectal cancers and usual pulmonary adenocarcinomas. American Journal Surgical Pathology; 29: 660 – 665.

- Khuder SA, (2001). Effect of cigarette smoking on major histological types of lung cancer: a meta-analysis. Lung Cancer 31: 139-148,.
- Ordóñez N; (2001). Value of thyroid transcription factor -1 immunostaining in distinguishing small cell lung carcinoma from other small carcinomas. American Journal Surgical Pathology 25: 363 – 372.
- Parkin DM, Whelan SL, Ferlay J, Teppo L, Thomas DB (2002). Cancer Incidence in Five Continents, Vol. VIII. IARC Scientific Publications No. 155. IARC Press: Lyon.
- Rekhi, B. et al, (2008). Clinicopathological features and the value of differential Cytokeratin 7 and 20 expression in resolving diagnostic dilemmas of ovarian involvement by colorectal adenocarcinoma and vice – versa. Diagnostic Pathology; 3: 39 – 45.
- Rossi, G. et al, (2007). Primary lung cancer presenting with gastrointestinal tract involvement: Clinicopathologic and immunohistochemical features in a series of consecutive cases. Journal of Thoracic Oncology ; 2: 115 – 120.
- Rubin BP, et al, (2001). Use of Citokeratin 7 and Citokeratin 20 in determining the origin of metastatic carcinoma of unknown primary, with special emphasis on lung cancer. European Journal of Cancer Prevention ; 10: 72 – 82.
- Sack M. J, et al, (1997). Cytokeratins 20 and 7 in the differential diagnosis of metastatic carcinoma in cytologic specimens. Diagnostic Cytopathology ; 16: 132 – 136.
- Tsao SC, et al, (2007). Use of caveolin – 1, thyroid transcription factor -1, and cytokeratins 7 and 20 in discriminating between primary and secondary pulmonary adenocarcinoma from breast or colonic origin. Kaohsiung Journal of Medical Sciences; 23: 325 – 331.
- Wang HL. et al, (2001). Immunohistochemical Distinction between primary adenocarcinoma of the bladder and secondary colorectal adenocarcinoma. American Journal Surgical Pathology; 25 (11): 1380 – 1387.
- Zamecnik J, Kodet R. (2002). Value of thyroid transcription factor-1 and surfactant apoprotein A in the differential diagnosis of pulmonary carcinomas: a study of 109 cases. Virchows Arch 440: 353-361.